



Abstract

Introduction: Total mandibular conventional dentures have a high degree of discomfort, leading to oral health problems, systemic and psychological level. Furthermore, the use of osseointegrated implants to replace teeth or prosthetic systems removable support may be limited when the amount and / or bone quality is insufficient. Thus, the use of mini implants is an alternative to narrow bone ridges.

Objective: The objective of this study was to evaluate overdentures retained by mini implants as definitive treatment option edentulous jaw in patients of the Health Center of San Bernardo, University of Los Andes, Chile.

Methods: A case series of 7 total prosthetically edentulous patients previously treated with conventional dentures and who met the inclusion criteria is presented. Each subject was interforaminales 4 mini implants inserted and the same day of surgery the prosthesis that the patient was carrying, transforming it into an implant retained overdenture was conditioned. Clinical and radiographic controls before and weekly during the first postoperative month and prosthetic fitting and at 4, 12 and 24 weeks were performed, considering the assessment of survival, success, vertical marginal bone level (VMBL), clinical attachment level (CAL), probing depth (PD), modified index plate (IPm), the bleeding on probing (BOP), the prosthetic condition and impact on quality of life of patients.

Results: After 6 months of follow-up, survival and success rate of 100% was obtained for implants. VMBL significant difference in bone loss with an average of 0.49 mm, the CAL with an average decrease of 0.35 mm and the PD with an average increase of 0.48 mm were observed. However, IPm, and BOP, showed no statistically significant differences. Only a prosthesis had a lower complication at 3 months was observed and an improvement in the quality of life of patients.

Conclusion: Overdentures retained by mini implants can be considered a successful therapeutic procedure for the treatment of mandibular edentulism, however, more studies are needed, with representative samples and monitoring to validate this therapy in the medium and long term.

Introduction

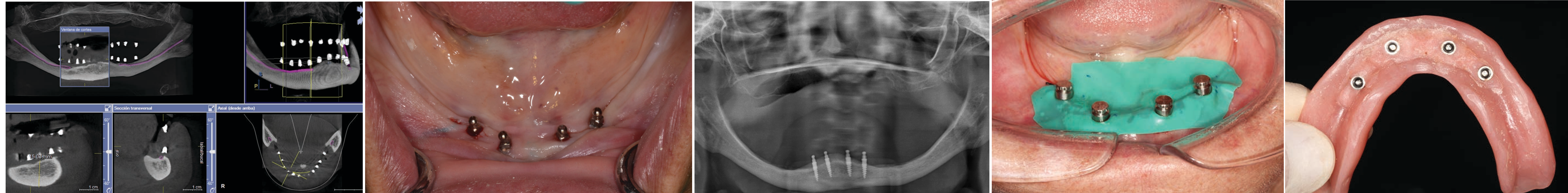Total mandibular conventional dentures have a high degree of discomfort due to their instability during use, leading to oral health problems, systemic and psychological level (1). This forces to seek new treatment options. Furthermore, the use of osseointegrated implants to replace teeth or prosthetic systems removable support may be limited when the amount and / or bone quality is insufficient. Thus, the use of mini implants is an alternative to narrow bone ridges (2-3). Considering the above, there is a need to review and synthesize the current evidence on clinical data available on the survival of MDI for definitive prosthetic treatment of edentulous and the impact that this type of therapy has on the quality of life of people who they receive it (4-5). The purpose of this study is to evaluate the definitive treatment of the edentulous jaw with overdentures, when MDI is used to hold and / or support the total prosthetic device in patients in the CESA of San Bernardo, University of Los Andes, Chile

Materials and Metods

A.Surgical planning stage: Orthopantomography and CBCT with the lower denture doubled in clear acrylic self-curing evaluating the quantity and quality of bone remaining is requested. (Fig N°1)

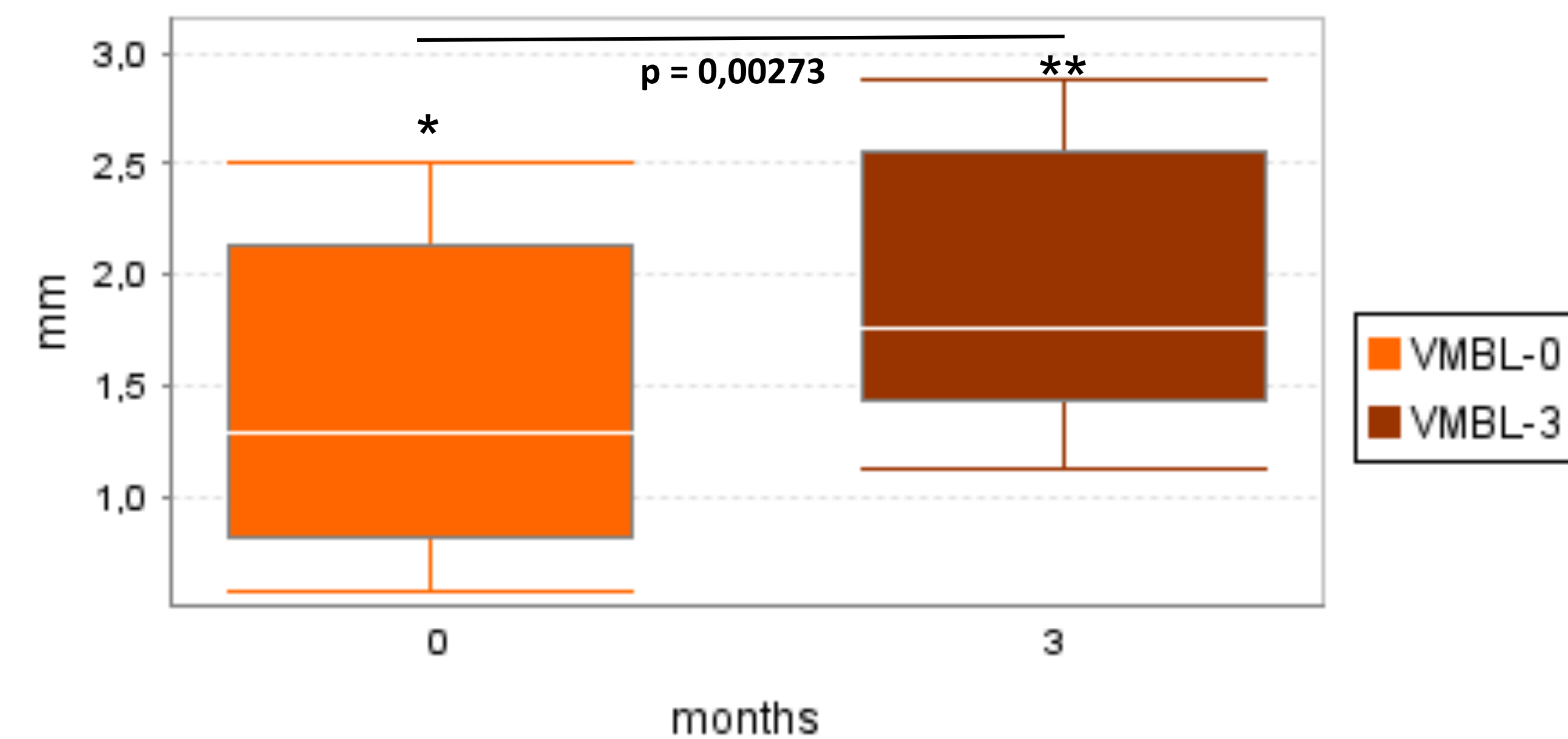
B.Surgical and prosthetic stage: Four MDI were inserted into the mandibular bony rim residual between mental foramen. The implants used were the Mini Drive Lock (MDL®) of the company Intra-Lock® Dental Implants (Intralock® International Inc., Boca Raton FL, USA.). (Fig. 2-5)

C.Clinical and radiographic controls: weekly during the first postoperative month and prosthetic fitting and at 4, 12 and 24 weeks are done, considering the assessment of survival, success, vertical marginal bone level (VMBL), clinical attachment level (CAL), the probing depth (PD), modified index plate (IPm), the bleeding on probe index (BOP), the prosthetic condition and impact on quality of life survey of patients.

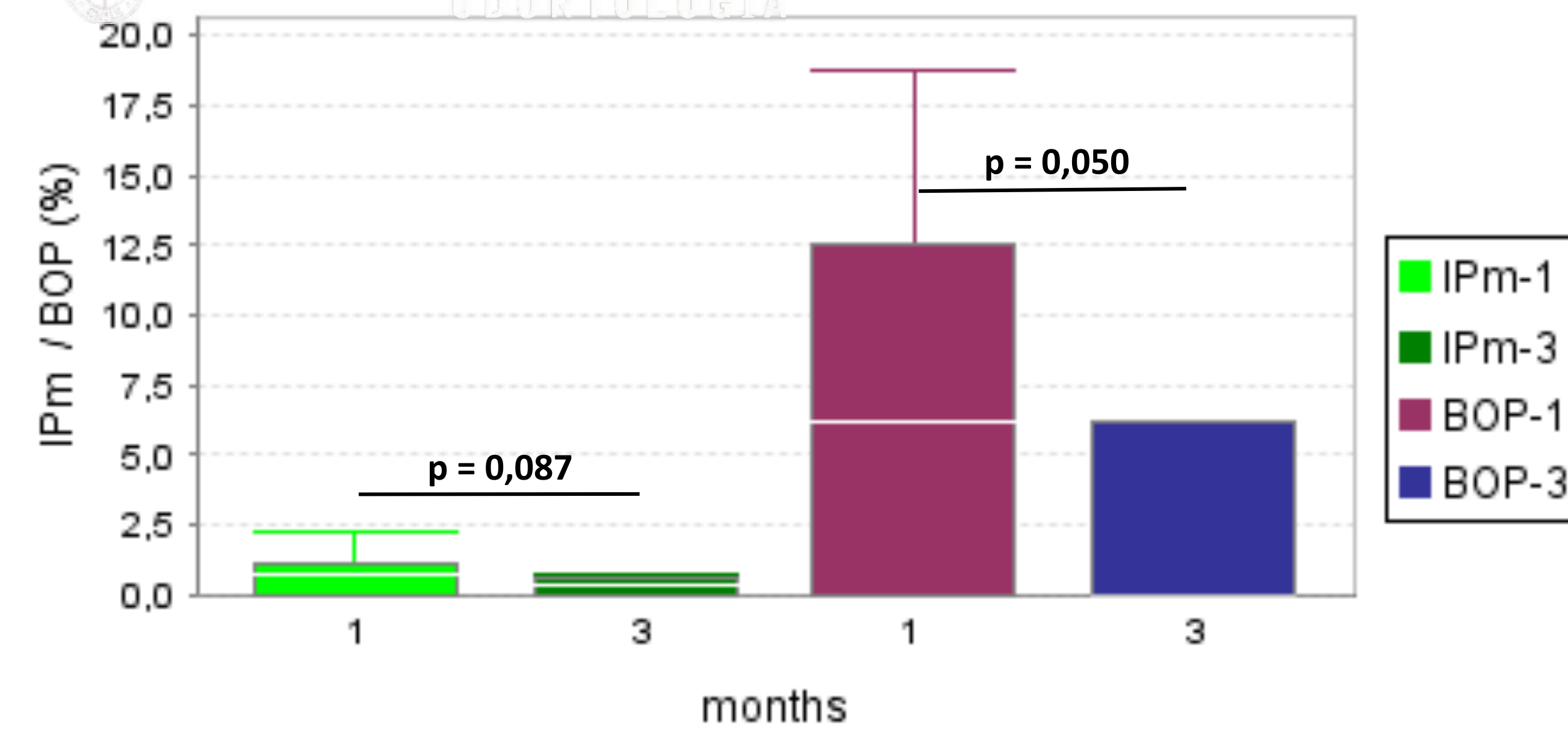


Results

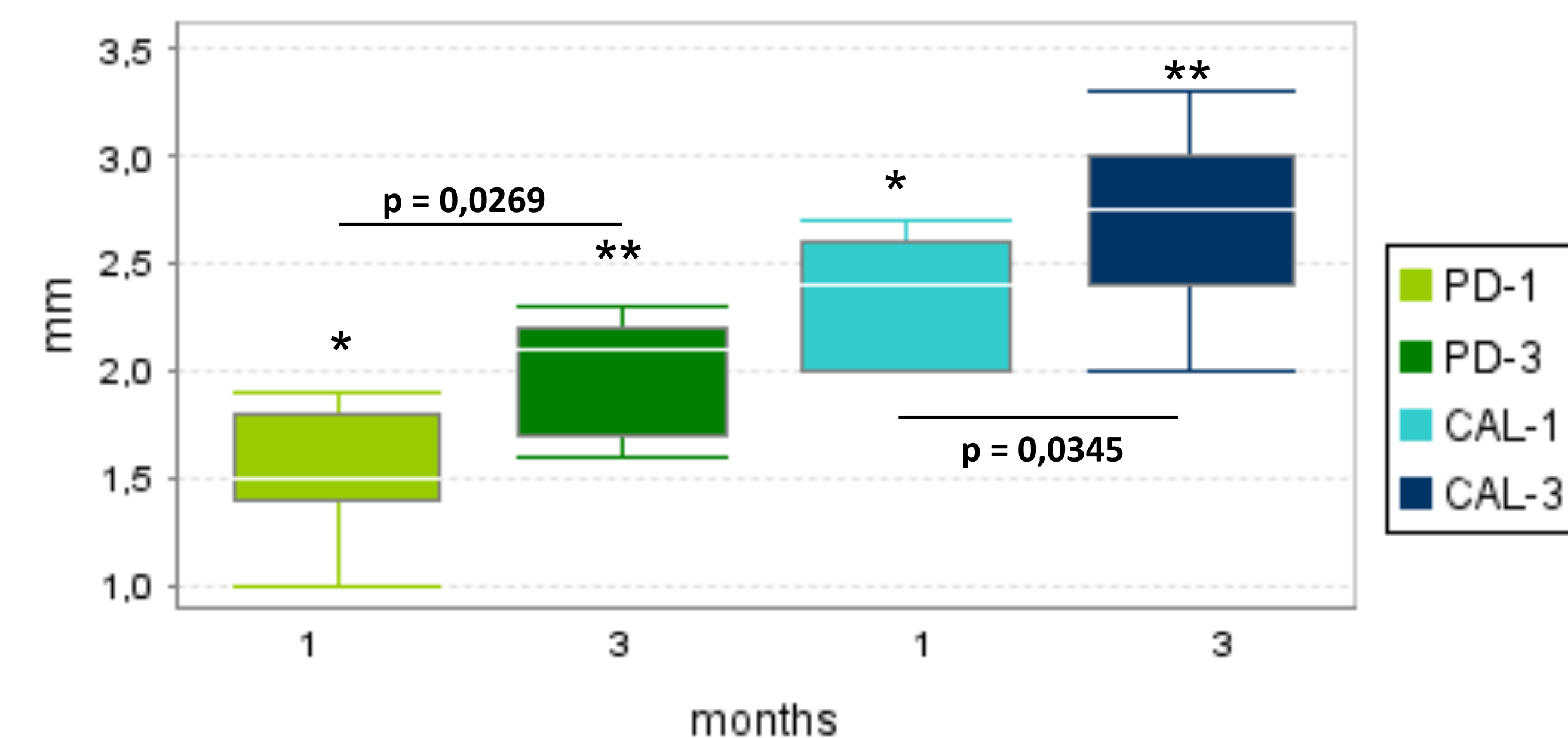
A. Comparison of radiographic VMBL on day 0 and three months after insertion MDI



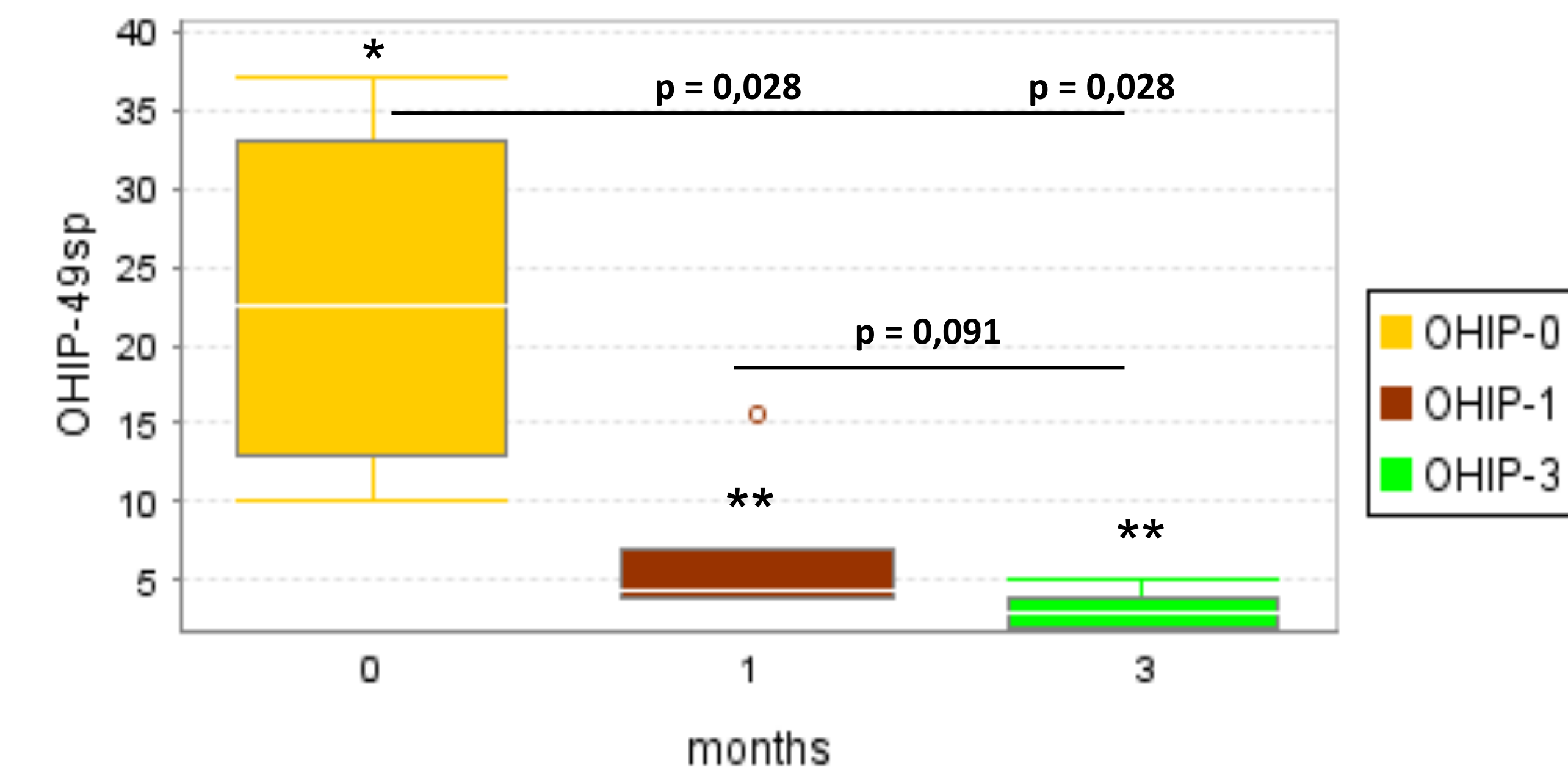
C. Comparison of IPm and BOP at month and three months of MDI installed



B. Comparison of CAL and PD at one month and three months of MDI installed



D. Comparing previous survey OHIP-49sp, 1 month and three months of MDI installed



Discussion

The elderly patients can have multiple systemic diseases that limit the possibility of submitting to surgery and/or to receive complex dental procedures. In this study, the overdenture onto MDI was obtained survival and success rates were 100%, which may indicate that might be a suitable definitive treatment option for total mandibular tooth loss. In evaluating the health indicators peri implant VMBL found that decreased on average 0.49 mm., the CAL decreased by 0.35 mm. and PD increased on average 0.48 mm. with statistically significant variations, however, estimates of the IPm and BOP, no statistically significant differences. Finally this study provides data about a significant improvement in the perception of quality of life related to oral health of patients treated with MDI and mandibular overdentures.

Conclusions

Considering the limitations of this research project it was recently initiated the following preliminary conclusions to the period of observation are obtained: considering the variables studied, overdentures on MDI could be considered as definitive treatment of the mandibular tooth loss in cases of limited bone availability besides providing a significant improvement in the quality of life of patients in relation to oral health. However, further studies are needed, with representative samples and monitoring to validate this therapy in the medium and long term.

Acknowledgements

The authors would like to thank Intralock® International Inc. for their support and manufacturing of all implants, Ramirez Valeria for performing statistical analysis, postgraduate program of oral rehabilitation and implantology at the University of Los Andes, Santiago of Chile and Education Division through School of Logistics Services, Chilean Army.

References

1. Vogel R, Smith-Palmer J, Valentine W. Evaluating the health economic implications and cost-effectiveness of dental implants: a literature review. Int J Oral Maxillofac Implants. 2013 Apr;28(2):343–56.
2. Bidra AS, Almas K. Mini implants for definitive prosthodontic treatment: a systematic review. J Prosthet Dent. 2013 Mar;109(3):156–64.
3. Preoteasa E, Imre M, Preoteasa CT. A 3-year follow-up study of overdentures retained by mini-dental implants. Int J Oral Maxillofac Implants. 2014 Oct;29(5):1170–6.
4. Akifusa S, Soh I, Ansai T, Hamasaki T, Takata Y, Yohida A, et al. Relationship of number of remaining teeth to health-related quality of life in community-dwelling elderly. Gerodontology. 2005 Jun;22(2):91–7.
5. Lopez R, Baelum V. Spanish version of the Oral Health Impact Profile (OHIP-Sp). BMC Oral Health. 2006;6:11.