Journal of Maxillofacial and Oral Surgery
MORE
Springer

A Pilot Study of Mini Implants as a Treatment Option for Prosthetic Rehabilitation of Ridges with Sub-Optimal Bone Volume

Anitha Balaji, Jumshad B. Mohamed, and R. Kathiresan

Additional article information

Abstract

Introduction

Implants are the latest development in the field of prothodontics, but still not widely used because of its expensive and its lengthier duration. Patients with ideal bone quantity and quality accommodate the conventional implants. The selection of the width of the implants has been widely speculated and the manufacturers have recently launched a series of ‘mini’ implants of narrower diameter. The long-term success rate of these narrow diameter implants, needs to be assessed.

Study

This 2 year retrospective study summarizes the recorded observations from 11 patients who received 2.4 mm diameter implants for single tooth restorations.

Results

One implant failed 10 months after loading. The success rate was 90.9%. The clinical evaluation of the peri implant mucosa using periodontal indices gave satisfying results for the implant–mucosa interfaces.

Conclusion

The success rate of the mini implants of 90.9%, is encouraging and hence studies involving larger number patients can be undertaken to study the efficacy of this novel treatment plan.

Keywords: Mini implants, Ridge deficiency, Implants

Introduction

Lack of bone width and inter-dental space has been regarded as an encumbrance in the case selection for prosthetic rehabilitation using dental implants. The patient would then have to be counseled for undergoing an augmentation or any additional procedure for the placement of the implant. However augmentation and additional procedures increase the duration of treatment, morbidity and mainly the cost of the complete treatment. The stipulated 'width' of bone required is governed by the minimum diameter of the implants available, which has been accepted as 3.75 mm. The logic or research supporting the selection of this diameter has been unclear.

Literature review show different results when using different diameter of implants. Animal study [1] of the influence of implant diameter on the integration of titanium screw shaped implants performed by measuring the peak torque required to shear off 6 mm long implants of varying diameters (3.0, 3.75, 5.0 and 6.0 mm) from the tibial metaphyses of rabbits, after 12 weeks of healing, showed a statistically significant increase of removal torque with increasing implant diameter. However, a similar study by Black et al. [2] infer that on comparison of the pull-out forces required to extract hydroxyapetite coated implants of 3.0, 3.3, and 4.0 mm diameter and 4, 8 and 15 mm length from dog bone after 15 weeks of integration, the ultimate pull out force correlated strongly to implant length, but not to diameter. Similarly, a study by Kido et al.

[3] that compared the pullout resistance of small and large diameter (3.25 and 4.25 mm) dental implants placed in the mandibles of five embalmed humans and the relationship of these implants to bone density. They conclude that though the maximum pullout force required for the large diameter implants was 15% greater than that required for the small diameter implants, the difference was not significant. However, a significant positive correlation has been observed between the pull-out resistance and the bone density for both the large and the small diameter implants ($P < 0.05$ and $P < 0.01$, respectively). However, the real clinical significance of torque and pull-out tests is controversial.

Some implant manufacturers have identified the challenge of minimal bone presence and made implants of a smaller diameter—they have been termed ‘mini implants.’ These mini implants have been reported to have been used as “interim” implants to support provisional prosthesis. On finding that these interim implants integrated well into the bone and was difficult to be removed later, the implant manufacturers recommend it for long-term usage. In August 2003, IMTEC Sendax MDI and MDI Plus were approved.

In the past decade, many implants ranging from 1.8 to 2.5 mm in diameter have been promoted for long-term applications [1–14].

These mini implants have been placed at the department of periodontology and oral implantology, Sree Balaji Dental College and Hospital. The aim of this retrospective study was to collect and summarize 2 years of clinical data on a group of patients treated with the use of 2.4 mm diameter mini—implants (Hitec, Life Care) for single—tooth restorations.

Materials and methods

Between June 2008 and September 2008 patients requiring single tooth replacements were selected as candidate for mini implants where inadequate bone was available for standard implant placement and available alveolar ridge width or inter-dental space was at least 5 mm. The patients were explained about the choice of implants with lesser width, the attendant risk and the possibility of undergoing augmentation procedure and then the insertion of the conventional width implant. Ethical committee approval was obtained for the same. A sample group of 11 patients (7 women and 4 men) were selected randomly and reviewed retrospectively. Four had lost their teeth due to dental trauma, four to dental decay, and three to periodontal disease (PD). The ages ranged from 20 to 52 years (mean age of 29.2). None of the patients suffered from any systemic disease (Table 1).

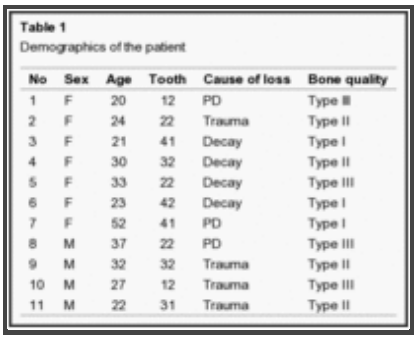

Table 1

Demographics of the patient

No	Sex	Age	Tooth	Cause of loss	Bone quality
1	F	20	12	PD	Type Ⅲ
2	F	24	22	Trauma	Type II
3	F	21	41	Decay	Type I
4	F	30	32	Decay	Type II
5	F	33	22	Decay	Type III
6	F	23	42	Decay	Type I
7	F	52	41	PD	Type I
8	M	37	22	PD	Type III
9	M	32	32	Trauma	Type II
10	M	27	12	Trauma	Type III
11	M	22	31	Trauma	Type II

Table 1

Demographics of the patient

Technique

Titanium screw implants, 2.4 mm in diameter, 13 mm in length were used (Hitec, Life Care). Under local anaesthesia crevicular incision placed in relation to the edentulous space, full thickness mucoperiosteal flap elevated. A 2 mm round bur used to mark the osteotomy site and 2 mm pilot drill used to prepare the osteotomy site up to 10 mm and mini implant placed in the prepared site. Wound closed using simple interrupted 3–0 silk sutures. All implants were immediately loaded with temporary crowns for 3 months followed by conventional crown reconstruction made of porcelain fused to metal. The occlusal surfaces of the crowns were designed to avoid premature contact during lateral and protrusive movements. Intraoral radiographic examination was performed using the paralleling technique. Basic clinical examination and radiographic evaluations were done pre-treatment, post operatively and periodic 3-month follow ups.

Radiographic films were observed using a magnifying lens to precisely reveal the implant threads and permit the measurement of marginal bone resorption accurately. Occlusal relationships and all complications recorded. Periodontal parameter data were compiled on peri-implant mucosal response, supra gingival plaque, gingival inflammation, bleeding on probing, amount of keratinized gingival around abutment and probing length from the gingival margin (Figs. 1, 2, 3, 4, 5, 6, 7, 8, 9, 10).

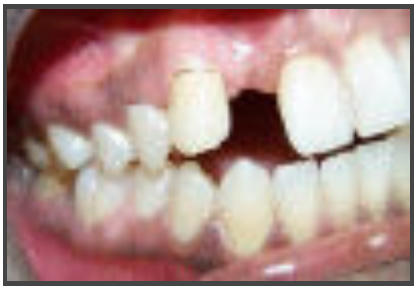

Fig. 1

Preoperative facial view of edentulous space

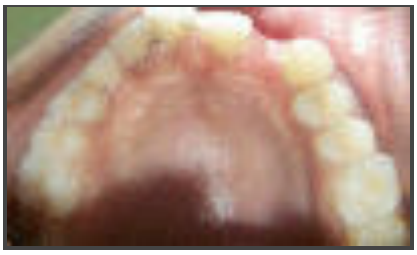
Fig. 2

Preoperative occlusal view of edentulous space

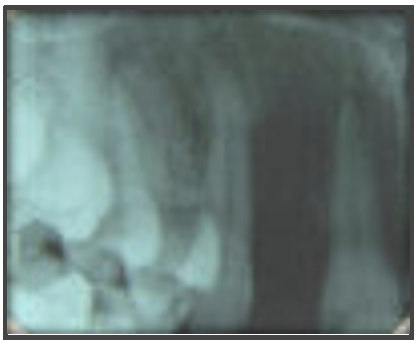
Fig. 3

Preoperative intraoral periapical radiograph

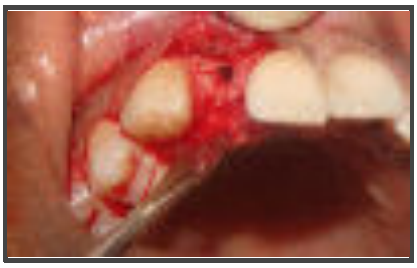
Fig. 4

Bone drilling for mini implant placement

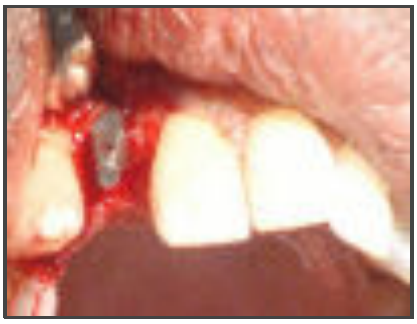
Fig. 5

Mini implant placed

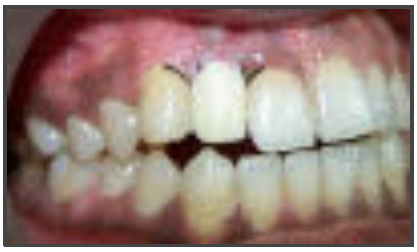
Fig. 6

Immediate loading with temporary

acrylic crown

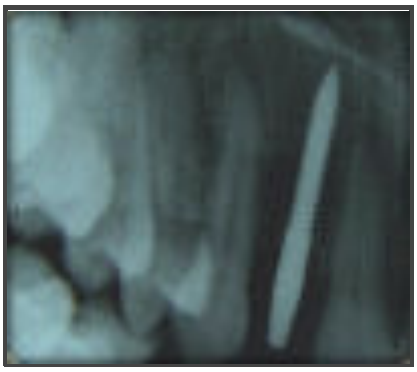

Fig. 7

Immediate postoperative periapical radiograph

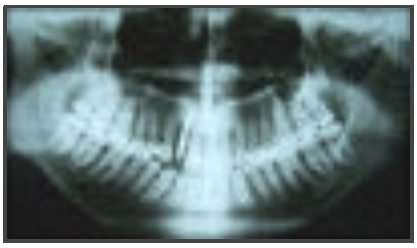

Fig. 8

OPG

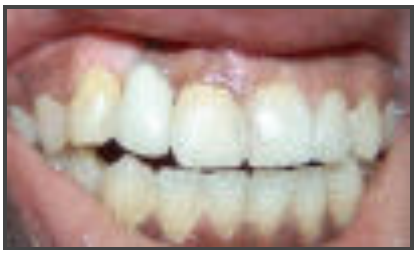

Fig. 9

Permanent crown

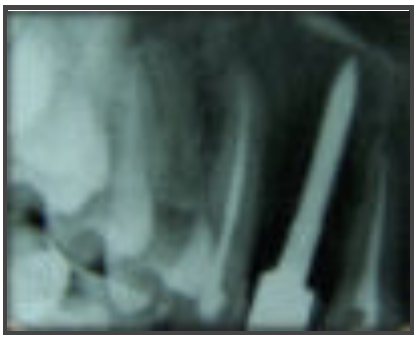

Fig. 10

Two-year intraoral periapical radiograph

Results

During the 2-year period of this study, 1 implant failed 2 months after loading. The success rate was 90.9%. The clinical evaluation of the peri implant mucosa using periodontal indices gave satisfying results for the implant-mucosa interfaces (Table 2).

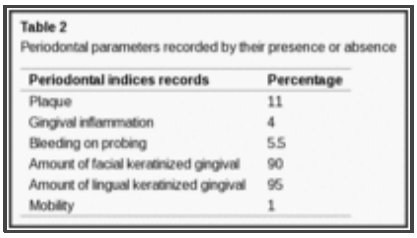

Table 2

Periodontal parameters recorded by their presence or absence

Periodontal indices records	Percentage
Plaque	11
Gingival inflammation	4
Bleeding on probing	5.5
Amount of facial keratinized gingival	90
Amount of lingual keratinized gingival	95
Mobility	1

Table 2

Periodontal parameters recorded by their presence or absence

The mean marginal bone resorption at the last check up, measured with the IOPA, from the first thread of the mini implant was 0.6 mm with a range of 0.4–1.2 mm.

Discussion

When inadequate bone is present for placement of standard-diameter implants, most practitioners suggest bone grafting either using autogenous bone or one of the many available bone substitutes. However, few patients wish to have or can meet the expense of, bone grafting or afford to give time for the graft to take up when the treatment needs to be performed in two stages. The expense of dental implant already is unaffordable for most patients, even when it does not accompany the added cost, trauma, pain and ambiguity of bone grafting. If dental implants are to achieve universal acceptance among all classes of dental patients, and not remain an “elite” treatment option, techniques that allow placement of implants in areas of remaining natural bone using minimally invasive procedures without grafting need to be devised. The mini diameter implants may be the answer to this challenge.

Griffitts et al. [4] in their study of 116 MDI implants achieved a success of 97.4% and conclude that mini implants, once conceived as transitional implants can be successfully used as permanent ones. They are relatively affordable and patient satisfaction is excellent.

However studies on the effect of width on pre-implant stress distribution and finite element stress analysis do suggest that wider implants present lesser peri-implant stress [5, 6].

Ertugrul and Pipko [7] in their study of morbidity of mini-dental implant (13 mm length and 2.2 mm in diameter) and Branemark root form implant, found that mini-dental implants can stand lateral forces for 35 min of loading, with non-zero first mobility. After 60 min, the first non-zero mobility value was measured with the Branemark implant under the same loads and conditions. However they summarize that, though mini-dental implants were less stable as compared to conventional Branemark implants under the same in vitro conditions, the mini dental implants are advantageous since they can be inserted in ridges with sub-optimal bone quantity. The surgical technique is simplified and does not rely on any unpredictable grafting techniques. The technique involves minimal surgery and less intricate prostheses. Therefore it presents less surgical morbidity and expenditure when compared to standard endosseous implants.

Flanagan [8–14] a proponent of the mini dental implants argues that there are implant diameters available from 1.8 to 7 mm. Intuitively a smaller diameter implant may present less of an impediment or obstacle for angiogenesis to the peri-implant bone. However, there also should be adequate bone density to resist occlusal forces placed on the implants via fixed prosthesis. The smaller surface area and volume of these implants places more force per square millimeter against the encasing bone than larger diameter implants, so there needs to be occlusal force control. Bone density of type I, II or III, bone site length of at least 4 mm, bone available length of at least 10 mm and at least 1 mm of attached or augmentable gingiva are desirable. Any intra oral location that exhibits these qualities may be appropriate. However, less dense bone may require the use of longer, small diameter implants to resist occlusal forces and present less per square mm of bone compression during service. That is, during function, lateral occlusal forces will exert a greater per square mm force against the supporting bone with smaller diameter implants that larger diameter implants. If the bone cannot resist this lateral compressive force, the implant may move in the bone and fibrous replacement may be initiated resulting in implant failure. Conversely, there may be physiological advantages to very small diameter implants. An advantage that very small diameter implants have over standard diameter implants is the lesser amount of linear or circumferential percutaneous exposure and bone displacement. The circumference of a 2 mm implant is

(22/7 × diameter) 6.28 mm. Whereas the circumference of a standard 4 mm diameter implant is 12.56 mm. The very small implant has half of the linear percutaneous exposure thus exposing less of the implant-gingival attachment to bacterial attack. There is also a small silhouette of the very small diameter implant that may present a barrier to angiogenesis and osteogenesis. Because dental implants are cylinders or near cylinders, a mathematic calculation of the outline form or the silhouette are, of a 2 × 10 mm implant may be compared with a 4 × 10 mm implant where the area is diameter(width) × height. So, $2 \times 10\ \text{mm} = 20\ \text{mm}^2$ and $4 \times 10\ \text{mm} = 40\ \text{mm}^2$. The 2 mm diameter implant presents a barrier of the osseous physiology that is half that of the

4 mm diameter implant. With respect to volume of the cylinder, where volume = (22/7 = 3.14) × (radius squared) × (cylinder height), then 3.14 × square mm × 10 mm = 31.4 mm^3 and, 3.14 × square mm × 10 mm = 125.6 cm^3. So to compare these volumes: 125.6/31.4 = 4. The 4 mm diameter implant has 4 times the osseous displacement as compared with the 2 mm diameter implant. This difference may be important. Intuitively, this may be a physiologic advantage for the very small diameter implant in that there may be more of an available osseous blood supply for the implant supporting bone or less of a barrier. In larger diameter implant this larger barrier to blood supply or angiogenesis may contribute to the classic “resorption to the first thread” in the larger

implant. The larger barrier may hinder angiogenesis and subsequent osteogenesis around a newly placed implant. Blood supply at the osseous crest may be hindered by the larger implant and produce the characteristic resorption to the first thread. This phenomenon does not seem to be prevalent with the 2 mm diameter implants.

The available bone for an implant site in many cases can leave much to be desired. In these cases, the occlusion, a reduced vertical dimension and ridge length can present a dimensional problem for space. Very small diameter implants can fit into many of these atrophic sites with adequate inter-implant and inter-occlusal spacing [8–14].

Several implantologists have, in the past decade, published several long-term results of good success of the mini-implants advocating their use for the bone-deficient cases [15–17].

Since bone volume and quality and ridge length can present implantologist with a challenge for restorative treatment, creative but effective solutions may need to be considered. An up-to-date knowledge of the array of implant sizes and shapes is an asset for treatment [8–14].

Conclusion

Within the limits of this study, we conclude that there was minimal failure rate in the mini implants we have placed for single tooth restoration can be a viable alternative in clinical situations in which the space problems do not permit the use of standard or wide diameter implants.

Article information

J Maxillofac Oral Surg. 2010 Dec; 9(4): 334–338.

Published online 2011 Feb 25.

doi: 10.1007/s12663-010-0152-2

PMCID: PMC3177481

PMID: 22190820

Anitha Balaji,[*] Jumshad B. Mohamed, and R. Kathiresan

Sree Balaji Dental College and Hospital, Chennai, India

Anitha Balaji, Email: dranitha@msn.com.

[*] Corresponding author.

Received 2010 Nov 13; Accepted 2010 Dec 4.

Copyright © Association of Oral and Maxillofacial Surgeons of India 2011

This article has been cited by other articles in PMC.

Articles from Journal of Maxillofacial & Oral Surgery are provided here courtesy of **Springer**

References

1. Ivanoff CJ, Sennerby L, Johansson C, Rangert B, Lekholm U. Influence of implant diameters on the integration of screw implants. An experimental study in rabbits. Int J Oral Maxillofac Surg. 1997;26:141–148. doi: 10.1016/S0901-5027(05)80837-9. [PubMed] [CrossRef]

2. Black MS, Delgado A, Fontenot MG. The effect of diameter and length of hydroxylapatite–coated

dental implants on ultimate pull out force in dog alveolar bone. J Oral Maxillofac Surg. 1990;48:174–178. doi: 10.1016/S0278-2391(10)80206-X. [PubMed] [CrossRef]

3. Kido H, Schulz EE, Kumar A, Lozada J, Saha S.